

Histological and Immunohistochemical Study of Fibrovascular Membranes in Patients with Advanced Diabetic Retinopathy and Vitrectomy Surgery with and without Prior Treatment with Ranibizumab

Ximena Mira Lorenzo^{1*}, Maricarmen Jiménez³, Aatzin Robles³, Arthur Levine², Benito Celis², Renata García Franco¹, Verónica Romero¹ and Abel Ramirez²

¹Retina and Vitreous Department, Nuestra Señora de la Luz Hospital Foundation, Mexico

²National Council of Science and Technology (CONACYT)/Conde de Valenciana Research Unit (UICONVAL), Mexico

³Mexican Institute of Ophthalmology, Mexico

*Corresponding Author: Ximena Mira Lorenzo, Retina and Vitreous Department, Nuestra Señora de la Luz Hospital Foundation, Mexico.

Received: December 05, 2018

Abstract

Background and Purpose: To describe the histological changes in fibrovascular membranes of patients who were exposed to intravitreal injection of ranibizumab in different days before pars plana vitrectomy surgery; to assess which of these days is the indicated for the placement of ranibizumab before the surgery to get the major benefits of the intravitreal drug.

Methods: It was a prospective, cross-sectional, descriptive experimental study conducted from March to November of 2010? in conjunction with the Research Unit of the Conde de Valenciana Foundation.

Patients diagnosed with Retinal tractional detachment were randomized in 4 groups:

- Group 1: No prior intravitreal injection of ranibizumab and vitrectomy.
- Group 2: Intravitreal injection of ranibizumab 4 days prior to vitrectomy.
- Group 3: Intravitreal injection of ranibizumab 5 - 10 days prior to vitrectomy.
- Group 4: Intravitreal injection of ranibizumab 15 - 37 days prior to vitrectomy.

Fibrovascular membrane samples were taken by 23G vitrectomy. Once obtained specimens, were fixed in formaldehyde at 20% and were embedded in paraffin. There were performed cuts of 5 μ and was done in these cuts standardized and controlled immunohistochemistry technique.

Results: Of 44 samples that were requested only 15 samples fibrovascular membrane were obtained (13 female patients and 2 male patients with age range 40 - 61 years). 13 patients diagnosed with tractional retinal detachment Grade 6 and 2 patients with tractional retinal detachment Grade 5.

Of these 15 samples there were only 9 samples during the procedure with paraffin.

It was necessary to eliminate the Group 4 which included patients with prior application of ranibizumab from days 15 to 37 by insufficient sample.

CD-117 marker was expressed in endothelial cells. In group 1 were 8 - 17 perforating vessels; in group 2 were 3 - 5 perforating vessels and in group 3 were 8 - 16 perforating vessels.

Conclusion: Histological changes in all three study groups were described, observing the expression of CD-117 marker only in endothelial cells with positivity of this marker in all groups. Day 4 post injection of ranibizumab was identified as the day that promotes pars plana vitrectomy because perforating vessels are fewer in number and have smaller caliber so this suggests lower activity of vascular endothelial growth factor and lower trans-surgical bleeding.

There are other pathways and molecules that regulate neovascularization and counteract the effect of ranibizumab. In addition, to the expression of CD-117 marker depends on the aggressiveness of the disease. So it is necessary to open new lines of research to identify other routes in this pathology.

Histological and immunohistochemical study of fibrovascular membranes in patients with advanced diabetic retinopathy and vitrectomy surgery with and without prior treatment with ranibizumab.

Keywords: Angiogenic; Diabetic; Fibrovascular; Histological; Immunohistochemistry; Intravitreal; Pars plana; Ranibizumab; Retinopathy; Vitrectomy

Introduction

Diabetic retinopathy remains to this day one of the leading causes of blindness in patients between 20 - 64 years of age in developing countries despite technological advances in ophthalmology. Retinal neovascularization is distinctive, and is the hallmark of diabetic retinopathy, it is considered a major risk factor for severe visual acuity loss in patients with diabetes mellitus. The Early Treatment Diabetic Retinopathy Study (ETDRS) showed that photocoagulation decreases 50% of severe visual loss in patients with high-risk features. According to the ETDRS panretinal photocoagulation can cause side effects such as cystoid macular edema and decreased vision. Approximately 4.5% of patients with diabetic retinopathy in the ETDRS underwent vitrectomy despite having prior photocoagulation [1].

The morbidity associated with proliferative diabetic retinopathy reflects the deleterious effects that exist with long-standing Diabetes Mellitus in retinal microcirculation. During the last two decades, the understanding of the cellular and subcellular microvascular retinal damage has led to discovery of vascular endothelial growth factor (VEGF) which is recognized as a permeable vessel factor. VEGF recently proved to be the main mediator of ocular neovascularization. This was subsequently confirmed when VEGF levels correlate with the severity of diabetic retinopathy. VEGF is a factor that induces vascular permeability which causes destruction of the fenestrations and tight junctions of the endothelial cells [2].

Currently the most common indication for vitrectomy in diabetic patients is the tractional retinal detachment involving the macula. Numerous studies have documented the benefit of surgical treatment of tractional retinal detachment with recent macula off. Vitrectomy in patients with macular tractional retinal detachment with macula on generally is not performed [3].

During the study to identify endothelial cells and the presence of VEGF we used the c-kit (C-117 marker), which is a proto-oncogene. In humans it is located in chromosome 4 (q11-21; locus W) encoding a protein tyrosine kinase type III receptor transmembrane, 145 kD, in the family which includes the PDGF receptor, M-CSF and FLT3 ligand, this means that is structurally similar to platelet-derived growth factor (PDGF) and colony stimulating factor (CSF).

Ranibizumab is an antibody fragment (Fab), having amino acid modifications that increases the affinity to all isoforms of VEGF which prevents binding of VEGF in all their corresponding receptors. In cases of active neovascularization the use of ranibizumab reduces the trans-surgical bleeding, and make easier the removal of fibrovascular membranes [4].

There are no studies or protocols describing the use of preoperative ranibizumab for advanced diabetic retinopathy cases as in the case of patients with tractional retinal detachment caused by fibrovascular membranes that causes traction.

Objective of the Study

- Describe the histological changes in fibrovascular membranes in patients who were exposed to intravitreal injection of ranibizumab in different days before pars plana vitrectomy surgery to define which of these days is the indicated for the ranibizumab injection prior to surgery to get the benefits of the anti-VEGF.
- Describe the histopathological and immunohistochemical changes with CD117 marker with fibrovascular membranes removed during pars plana vitrectomy in patients with tractional retinal detachment untreated and previously treated with ranibizumab.

Specific objectives

1. Determine the number of perforating vessels per sample.
2. Determine the expression and positivity for CD-117 marker.

Material and Methods

It was a prospective, cross-sectional, descriptive experimental study conducted from March to November in conjunction with the Research Unit of the Conde de Valenciana Foundation.

Inclusion criteria

- Patients with tractional retinal detachment diagnosis
- Patients with pars plana vitrectomy after the injection of ranibizumab.
- Patients with informed consent.

Exclusion criteria

- Patients with prior intravitreal injection of ranibizumab or bevacizumab.
- Patients with less than 3 months of retinal photocoagulation.

Elimination criteria

- Patients who did not meet prior photographic record.
- Samples not obtained during surgery.
- Insufficient sample.

Diabetic retinopathy patients with tractional retinal detachment were included which underwent imaging eye study before surgery to classify tractional retinal detachment according to Elliot Classification [9]:

1. Posterior Vitreous Detachment overall.
2. Focal vitreoretinal adhesion.
3. Extensive vitreoretinal adhesions
4. Adhesion including optic nerve, macula and vitreous detached arcades to the periphery.
5. Vitreoretinal adhesion to the optic nerve of the arches to the periphery.
6. Complete vitreoretinal adhesion.

Subsequently, 0.5 mg of ranibizumab was injected in 0.05 ml of a single intravitreal dose with sterile technique in the upper temporal quadrant 3.5 mm in pseudophakic and 4.0 mm in phakic patients, patients before pars plana Vitrectomy to 23G.

The patients were divided into 4 groups:

1. **Group 1:** No prior intravitreal injection of ranibizumab before vitrectomy.
2. **Group 2:** Intravitreal injection of ranibizumab 4 days before vitrectomy.
3. **Group 3:** Intravitreal injection of ranibizumab 5 - 10 days before vitrectomy.
4. **Group 4:** Intravitreal injection of ranibizumab 15 - 37 days before vitrectomy.

Three samples of each group for triplet samples to confirm findings and avoid bias were obtained. During pars plana vitrectomy fibrovascular membrane sample delamination or segmentation technique according to surgeon preference was taken.

The samples were placed inside eppendorf tubes with 2 ml of 4% Formalin and after that, the samples were embedded in paraffin. The immunohistochemistry study was performed with CD117 marker.

Cuts of 4 - 5 μ without paraffin were made, they were dehydrated and graded with xylol and alcohol (70%, 50% and 20%) and water. PBA samples were washed for 5 minutes. Subsequently they were incubated in hydrogen peroxide of 3% for 5 minutes at room temperature to remove endogenous peroxidase activity. Washing was performed with water and PBS tween for five minutes each sample and these sections were incubated for 30 min with monoclonal antibody to VEGF CD-117 marker. At the end was placed streptavidin. The tissue was photographed to measure the entire thereof area, C-117 reactivity value, assessing vascular tissue, presence or absence of blood vessels, fibroblast cells and fibrous elements of each specimen.

Results

Of 44 samples that were requested, only 15 samples of fibrovascular membrane were obtained: (13 female patients and 2 male patients with age range 40 - 61 years). 13 patients were diagnosed with tractional retinal detachment Grade 6, and 2 patients with tractional retinal detachment Grade 5.

Of these 15 samples, there were only 9 samples during the procedure with paraffin.

It was necessary to eliminate the Group 4 which included patients with prior application of ranibizumab from days 15 to 37 by insufficient sample.

Group 1 was the control group, included 3 patients who had tractional retinal detachment Grade 5 and Grade 6 who underwent 23G vitrectomy without ranibizumab. The endothelial cells were positive to CD 117, the perforating vessels were present from 8 to 17 in each sample (Table 1 and figure 1).

Patient	Age	Tractional retinal detachment	CD-117	Perforating vessels
1	47	Grade 5	+	8
2	47	Grade 6	+	2
3	49	Grade 5	+	17

Table 1: Group 1 characteristics.

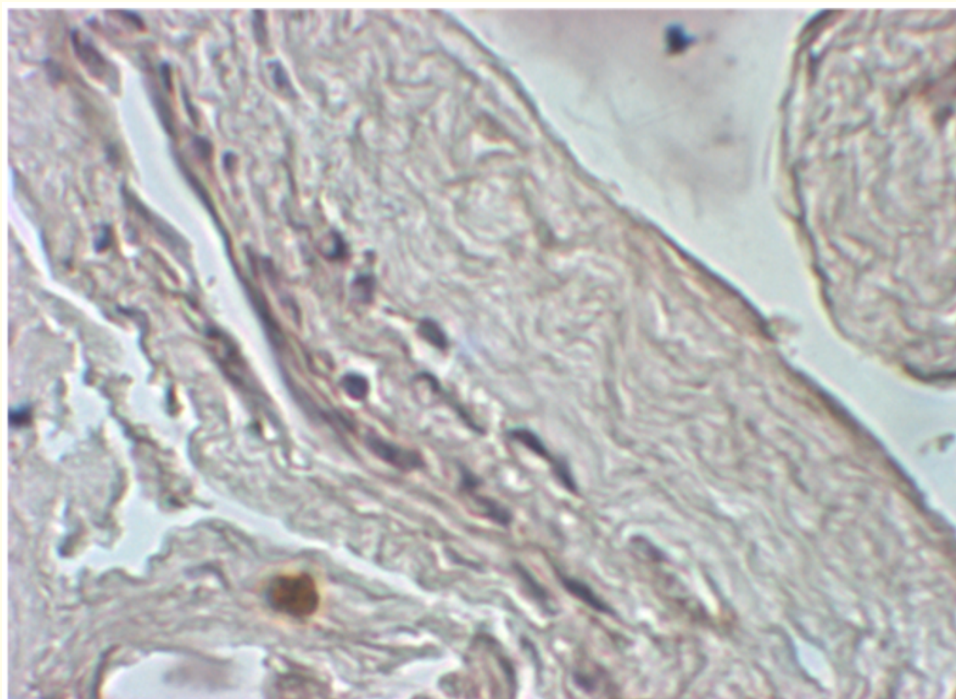


Figure 1: A vessel of large size and multiple perforating vessels with positivity for CD-117 is observed.

Histological and Immunohistochemical Study of Fibrovascular Membranes in Patients with Advanced Diabetic Retinopathy and Vitrectomy Surgery with and without Prior Treatment with Ranibizumab

Group 2 included 3 patients with intravitreal injection of ranibizumab 4 days prior to vitrectomy. The endothelial cells were present and positive for CD117 and the perforating vessels decreased from 3 to 5 in the samples (Table 2 and figure 2).

Patient	Age	Tractional retinal detachment	CD-117	Perforating vessels
4	61	Grade 6	+	5
5	60	Grade 6	+	4
6	50	Grade 6	+	3

Table 2: Group 2 characteristics.

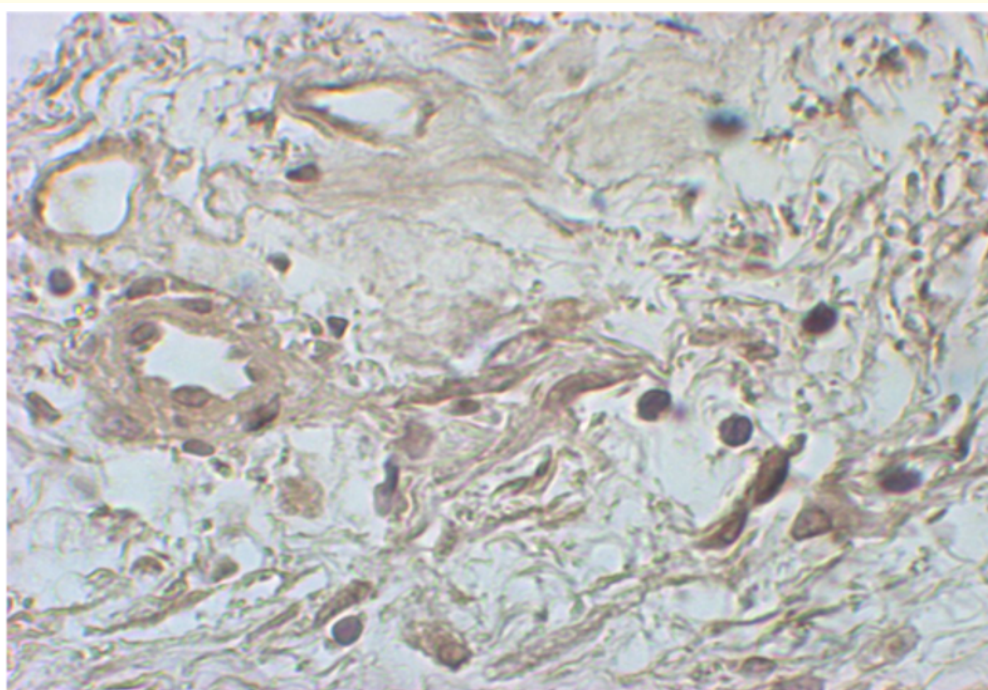


Figure 2: Narrowing of the vessels is observed as well as decreased perforating vessels.

Group 3 included 3 patients with intravitreal injection of ranibizumab 5 - 10 days prior to vitrectomy, the endothelial cells were present and positive for CD 117, the perforating vessels were present and increased in number from 12 to 17 in the samples (Table 3 and figure 3).

Patient	Age	Tractional retinal detachment	CD-117	Perforating vessels
7	52	Grade 6	+	16
8	41	Grade 5	+	8
9	41	Grade 5	+	12

Table 3: Group 3 characteristics.

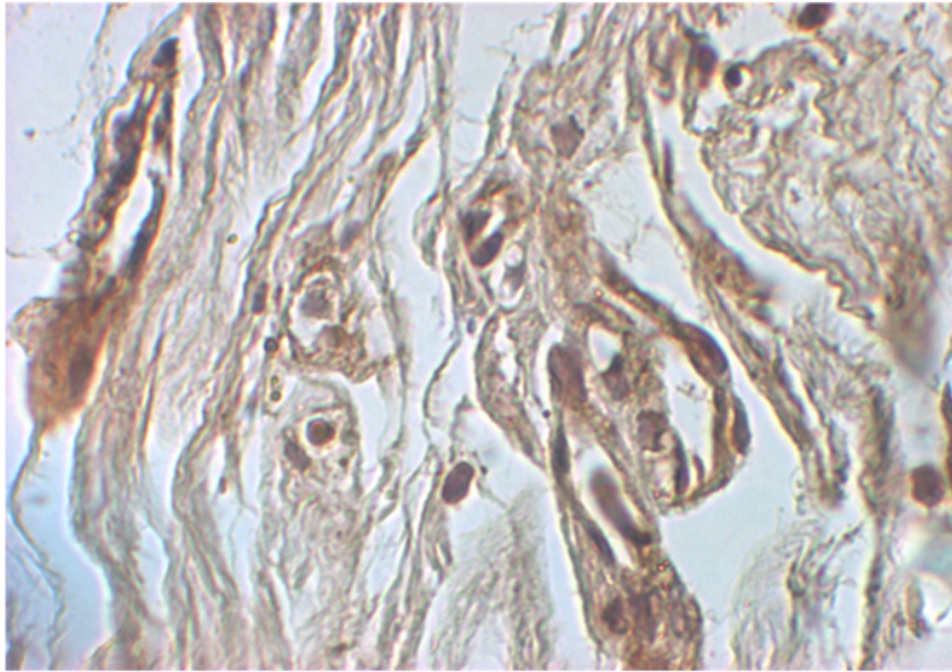


Figure 3: Numerous perforating vessels and increased vessel caliber is observed.

In all samples sparse fibrous tissue, scarce inflammatory cell pigmented cells were perivascular and both inside and outside the vessel were observed.

Endothelial cells were observed and present in all the study groups. In group 2 and 3 the endothelial cell size was significantly decreased. Being cells positive to CD-117 marker, indicates proliferative activity and presence of VEGF.

Perforating vessels were observed with larger caliber in the control group, in group 2 it was noticed that the number of perforating vessels and the caliber of them decreased and it was noteworthy that in group 3, the number of perforating vessels compared with the control group, was increased.

Discussion

In this study we observed that endothelial cells are present in all groups and are positive for CD-117 marker. It was interesting to observe significantly decreased positive endothelial cells to CD-117 on day 4 post injection of ranibizumab. It might be assumed that before to surgery there is a higher concentration of the anti-VEGF and then the anti-VEGF decreases endothelial cells size. Also, in patients 10 days after injection, we observed increased number of endothelial cells and we assume that at this point the concentration of ranibizumab had decreased to the 50% which produced an over expression of angiogenic molecules such as platelet derived growth factor, metalloproteinases, erythropoietin and many other molecules that could counteract the activity of ranibizumab, perpetuating the damage and maintaining the activity of the disease [5].

Histological and Immunohistochemical Study of Fibrovascular Membranes in Patients with Advanced Diabetic Retinopathy and Vitrectomy Surgery with and without Prior Treatment with Ranibizumab

There is a paper published by Kubota, *et al.* that included 5 patients who were injected with bevacizumab between 4 - 14 days prior to surgery where they found that their samples were positive for CD 34 in endothelial cells that were similar to capillary structures. The control group compared the density of CD 34 and there was no significant difference between them. They described the presence of endothelial cells after bevacizumab injection so that it could decrease briefly the described neovessels, but not the regression of neovascularization and when the effect of bevacizumab decreases the neovessels are reperfused. It was clear that the decrease in the fenestrations of the neovessels in both groups was due either to prior bevacizumab, or in the control group with previous photocoagulation [6].

Ranibizumab was approved by the FDA in December 2004 for intraocular use; is an antibody fragment (Fab), having amino acid modifications to increase the affinity to all isoforms of VEGF which prevents binding of VEGF in all their corresponding receptors. The absence of the constant portion promotes systemic elimination, thereby reducing systemic exposure and therefore reduces the possibility of cytotoxicity and inflammation. After intravitreal injection, dose dependent ranibizumab acts in the vitreous, retinal tissue and aqueous humor. Furthermore studies in animals after multiple dose intraocular application and steady serum concentration was observed indicating the absence of accumulation of the drug [7].

It has been demonstrated the persistence of the drug in the vitreous for 29 days with an average life of 2.84 days, reaching the choroid between the first and fourth day without finding drug concentrations in the fellow eye at a dose of 0.5 mg of intravitreal ranibizumab [8].

There are reports that suggest that preoperative antiangiogenic facilitates vitrectomy in cases with severe proliferative retinopathy. In cases of active neovascularization the use of ranibizumab reduces trans-surgical bleeding, improving the removal of fibrovascular membranes. Intravitreal anti VEGF generally applied 1 week previously, allows the regression of neovascularization upon vitrectomy. A disadvantage is that the neovascular tissue undergoes shrinkage promoting the progression of tractional retinal detachment [9].

Conclusion

Histological changes in the three study groups were described, observing the expression of CD-117 marker only in endothelial cells with positivity of this marker in all groups. Day 4 post Ranibizumab injection was identified as the day that improves the surgical technique; pars plana vitrectomy because perforating vessels are fewer in number and have smaller caliber, so this suggests lower activity of vascular endothelial growth factor and lower trans-surgical bleeding.

There are other pathways and molecules that regulate neovascularization and counteract the effect of Ranibizumab. In addition, to the expression of CD-117 marker depends on the aggressiveness of the disease. So it is necessary to open new lines of research to identify other routes in this pathology.

Bibliography

1. Early Treatment Diabetic Retinopathy Study (ETDRS) Research Group. "Photocoagulation for diabetic macular edema: Early Treatment Diabetic Retinopathy Study report number 1". *Archives of Ophthalmology* 103.12 (1985): 1796-1806.
2. Caldwell RB., *et al.* "Vascular endothelial growth factor and diabetic retinopathy: pathophysiological mechanisms and treatment perspectives". *Diabetes/Metabolism Research and Reviews* 19.6 (2003): 442-455.
3. Ho T., *et al.* "Vitrectomy in the management of Diabetic Eye Disease". *Survey of Ophthalmology* 37.3 (1992): 190-202.
4. Rosenfeld PJ., *et al.* "Ranibizumab for Neovascular Age-Related Macular Degeneration". *New England Journal of Medicine* 355 (2006): 1419-1431.

Citation: Ximena Mira Lorenzo., *et al.* "Histological and Immunohistochemical Study of Fibrovascular Membranes in Patients with Advanced Diabetic Retinopathy and Vitrectomy Surgery with and without Prior Treatment with Ranibizumab". *EC Ophthalmology* 10.3 (2019).

Histological and Immunohistochemical Study of Fibrovascular Membranes in Patients with Advanced Diabetic Retinopathy and Vitrectomy Surgery with and without Prior Treatment with Ranibizumab

5. Kushiaki K., *et al.* "Histology of fibrovascular membranes of proliferative diabetic retinopathy after intravitreal injection of bevacizumab". *Retina* 30.3 (2010): 468-472.
6. Patwell D., *et al.* "Fibrous Membranes in Diabetic Retinopathy and Bevacizumab". *Retina* 30.7 (2010): 1012-1016.
7. Ferrara N., *et al.* "Development of ranibizumab, an anti-vascular endothelial growth factor antigen binding fragment, as therapy for neovascular age-related macular degeneration". *Retina* 26.8 (2006): 859-870.
8. Abdallah W., *et al.* "Anti-VEGF Therapy for Proliferative Diabetic Retinopathy". *International Ophthalmology Clinics* 49.2 (2009): 95-107.
9. Elliot D., *et al.* "Diabetic tractional retinal detachment". *International Ophthalmology Clinics* 49.2 (2009): 153-165.

Volume 10 Issue 3 March 2019

©All rights reserved by Ximena Mira Lorenzo., *et al.*